



A Novel Strategy for Bone Integration and Regeneration: Case Studies

Photofunctionalization of Dental Implants and Ti Mesh

Akiyoshi Funato, DDS
Ryohei Tonotsuka, DDS
Hiroshi Murabe, DDS
Makoto Hirota, DDS, PhD
Takahiro Ogawa, DDS, PhD



PREVIEW: Click here to see a preview of the educational video.

WATCH NOW: Click here to view the entire DentalXP video.
Username: aacdxxx (where the X's represent your AACD member number). Password: dentalxp

Abstract

Ultraviolet light treatment of dental implants immediately prior to placement, or *photofunctionalization*, is a novel clinical tool with the potential to improve implant therapy. Photofunctionalization improves the surface properties of titanium surfaces by removing hydrocarbons, regenerating hydrophilicity, and optimizing electrostatic properties. We photofunctionalized dental implants and titanium mesh (Ti mesh) in two complex clinical cases requiring simultaneous guided bone regeneration, sinus elevation, immediate implant placement into the extraction socket, and esthetic consideration. The use of photofunctionalized implants and Ti mesh facilitated more strategic and aggressive treatment planning and resulted in successful treatment outcomes with secure application of immediate and early loading protocols. In vitro, the number of attached osteoblasts and the level of alkaline phosphatase activity were substantially increased on photofunctionalized Ti mesh, providing validation of the enhanced osteoconductive properties of photofunctionalized Ti mesh. An overview of the principles of photofunctionalization and practical guidance on its clinical use are presented. The clinical cases discussed here, along with the suggested technical guidance and research data, suggest that photofunctionalization is a useful and effective tool for improving implant therapy by enabling novel avenues of treatment and overcoming common challenges in current implant dentistry.

Key Words: photofunctionalized implants, UV, bone augmentation, Ti mesh, hydrophilic, osseointegration

Introduction

Ultraviolet (UV) light treatment of dental implants immediately prior to placement, known as *photofunctionalization*, has drawn considerable interest and attention as a novel and viable clinical tool for improving outcomes in implant therapy.¹⁻⁵ A significant number of implant cases require the site-development surgery to secure implant stability, obtain optimal esthetics, and ensure longevity. A common biological event for establishing osseointegration and pre-implant bone augmentation is the interaction between osteogenic cells and titanium materials. This article presents two clinical cases that successfully restored complex situations using photofunctionalized dental implants and titanium mesh (Ti mesh). Also presented are the theoretical and technical rationale for photofunctionalization and clinically relevant *in vitro* data that show an increased osteoconductivity of photofunctionalized Ti mesh.

Photofunctionalization

Dental implants are hydrophobic and covered with the hydrocarbons that always accumulate during normal aging (Fig 1).^{4,7} Photofunctionalization is the rapid, chairside conditioning of dental implants using UV light that results in the removal of hydrocarbons, regenerates hydrophilicity, and optimizes the electrostatic properties of the implant surfaces (Fig 1).^{4,8-10} The improved surface properties have been shown to enhance specific biological events necessary for osseointegration (Fig 2). Photofunctionalization increases the strength of osseointegration threefold during the early stages of healing in animal models and results in an increase in bone-implant contact from 53% to 98.2%, virtually a maximal level of osseointegration.⁸

Specifically, photofunctionalization improves implant surfaces by (1) removing surface carbon that unavoidably accumulated on the surface during the biological aging of titanium, (2) regenerating superhydrophilicity that had been lost during the biological aging of titanium, and (3) optimizing the electrostatic status of the surface. Note that the presence of hydrophilicity alone does not improve the osteoconductivity of implants as significantly as when the three prerequisites of osseointegration are met.

In humans, a study involving a large number (90%) of complex cases showed that the healing time before functional loading was 3.2 months in photofunctionalized implants and 6.5 months in as-received implants.¹ There was no negative impact of the substantially accelerated loading on the success rate up to the follow-up period of 2.5 years. The speed of osseointegration, as evaluated by the implant stability quotient (ISQ) increase per month, is 3 to 20 times greater for photofunctionalized implants than as-received implants reported in the literature.^{1,3} Clinical and animal studies reported the preservation, and in some cases even a gain, of the marginal bone level after receiving photofunctionalized implants.^{2,11,12} The bone-implant interface at the marginal area was more intensively mineralized around photofunctionalized implants, suggesting that the quality of marginal bone was enhanced around photofunctionalized implants.¹¹ Photofunctionalization is effective for all the titanium surfaces tested, as shown by hydrophobic to hydrophilic surface changes of various dental implants (Fig 1).^{13,14} Hemophilicity, as shown by blood spiraling up the implant surface, can be seen around photofunctionalized dental implants as soon as they make contact with the implant site, in contrast to untreated controls (Figs 3a & 3b).

Biological Validation of Photofunctionalized Ti Mesh

In addition to the acceleration and enhancement of bone-implant integration, the potential effect of photofunctionalization is to improve the interaction of biological cells and tissues with various biomaterials. Given the principle and mechanism behind photofunctionalization (i.e., carbon removable and hydrophilicity regeneration), photofunctionalization should be effective as long as the biomaterial is titanium- or titanium alloy-based. Among titanium-based biomaterials used in conjunction with implant therapy, Ti mesh could be a potential target of improvement because of its large area interfacing with existing and regenerating bone. Probably due to the improved biocompatibility, the anti-inflammatory effect of photofunctionalized Ti mesh is routinely experienced in clinical situations by the reduced manifestation of postoperative swelling and flare reaction, and the accelerated soft tissue wound healing. The percentage of post-implant surgery complications, including the chance of Ti mesh exposure, tissue dehiscence, and infection, can be reduced from 4.95% to 0.59% by applying photofunctionalization.¹ However, the potential effect of photofunctionalization to enhance the osteoconductivity of Ti mesh has not been examined, prompting us to perform the *in vitro* experimental study discussed in this report. Human mesenchymal stem cell-derived osteoblasts were cultured on Ti mesh with and without photofunctionalization using a previously established experimental protocol.¹⁵ Photofunctionalization was performed for 15 minutes using a photo device (TheraBeam Affinity, Ushio; Tokyo, Japan). After 24 hours of culture, a greater number of osteoblasts attached on photofunctionalized Ti mesh than on untreated Ti mesh. As a result, an approximately five times greater area of Ti mesh was covered by osteoblasts, as seen in confocal microscopy images (Fig 4a). In addition, the behavior of the cells was significantly improved. The cells were immunochemically stained for cytoskeletal actin (red) and adhesion protein, vinculin (green). A histogram showing the area of cell coverage (osteoblasts occupation in % area on Ti mesh) is also presented (Fig 4b).




Figure 1: The rapid, chairside conversion from hydrophobic to hydrophilic surfaces on all commercial dental implants by photofunctionalization.

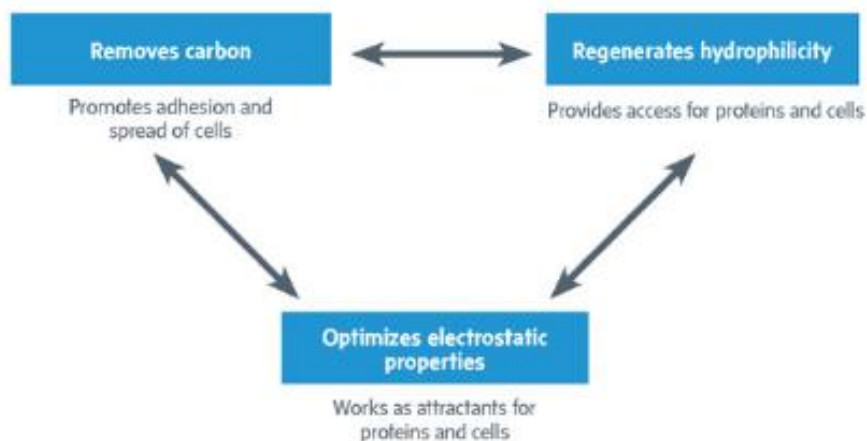
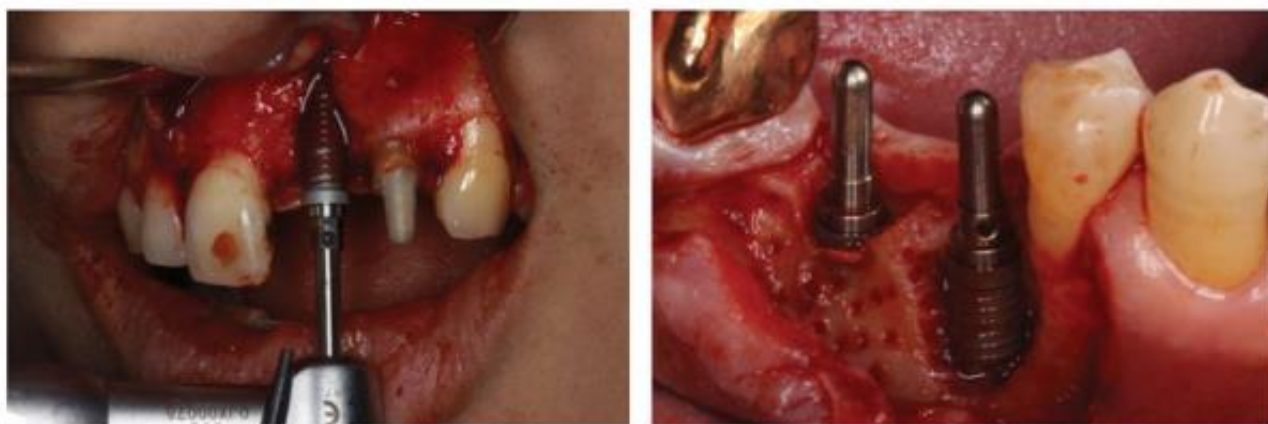

Figure 2: Photofunctionalization regains the prerequisites for osseointegration that have been lost or substantially compromised during biological aging of titanium.



Figures 3a & 3b: Typical clinical images depicting hemophilic surfaces of photofunctionalized dental implants.

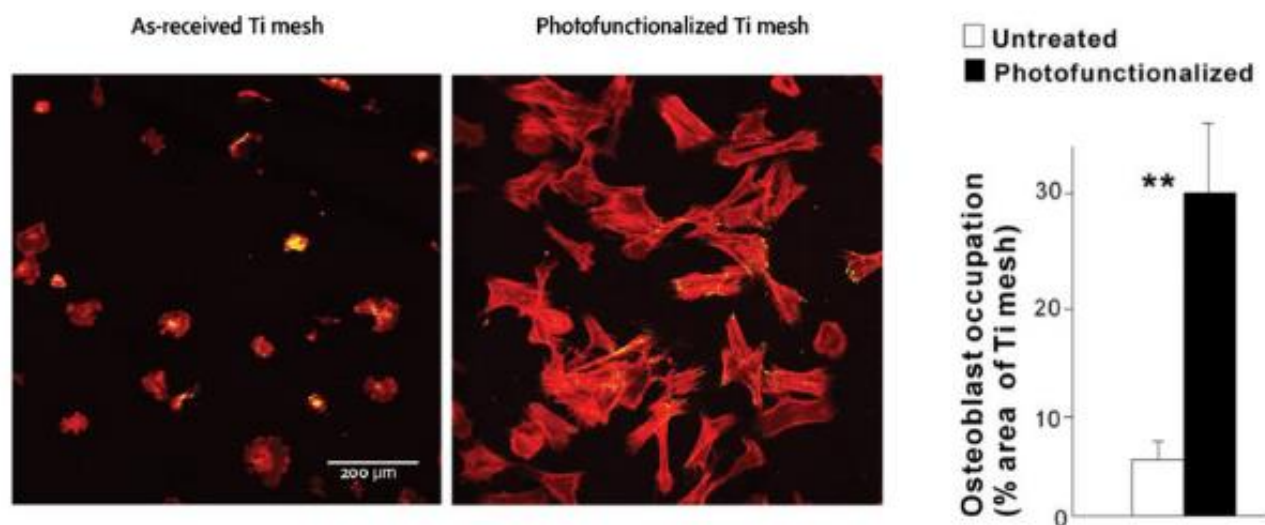


Figure 4a: Larger area of osteoblast coverage on photofunctionalized Ti mesh. Confocal microscopic image of human osteoblasts cultured on as-received Ti mesh and photofunctionalized Ti mesh 24 hours after seeding.

Figure 4b: Histogram showing the area of cell coverage (osteoblasts' occupation in % area on Ti mesh). ** $p < 0.01$, statistically significant between as-received and photofunctionalized Ti mesh.

// A common biological event for establishing osseointegration and pre-implant bone augmentation is the interaction between osteogenic cells and titanium materials. //

The cells spread and settled more quickly on photofunctionalized Ti mesh, and there was increased expression of actin (a cytoskeletal protein) and vinculin (an adhesion protein) in cells on photofunctionalized Ti mesh (Fig 5a). The results from cytomorphometry and protein expression densitometry are also presented (Fig 5b).

Culture images after alkaline phosphatase (ALP) stain and the result from ALP chemical quantification are shown (Figs 6a & 6b). The expression of ALP, an early marker of osteoblastic function, was considerably greater in cells on photofunctionalized Ti mesh. These results indicated that photofunctionalization of Ti mesh significantly increased the number of osteoblasts attached, enhanced the adhesion and retention of cells on Ti mesh, and expedited the osteogenic function in the cells.

Case Reports

Case 1: Fixed Implant Restoration with Simultaneous GBR in the Esthetic Zone Using Photofunctionalized Implants and Ti Mesh

Securing three-dimensional shape of bone and soft tissue (e.g., contour, height, and thickness) holds a key to successful implant restoration in esthetic cases.¹⁶⁻¹⁸ A 46-year-old female presented with a dislodged bridge and root fractures in the anterior maxilla. Two months after teeth #7 and #9 were extracted, photofunctionalized implants (4 mm in diameter and 13 mm in length, Osseotite Certain, BIOMET 3i, West Palm Beach, FL) were placed at these sites. Photofunctionalization was performed by treating the implants with UV light for 15 minutes (Fig 7a), using a photo device (TheraBeam Affinity) at chairside immediately prior to implantation (Fig 7b). Simultaneous guided bone regeneration (GBR) was performed

Photofunctionalization increases the strength of osseointegration threefold during the early stages of healing in animal models and results in an increase in bone-implant contact from 53% to 98.2%, virtually a maximal level of osseointegration.

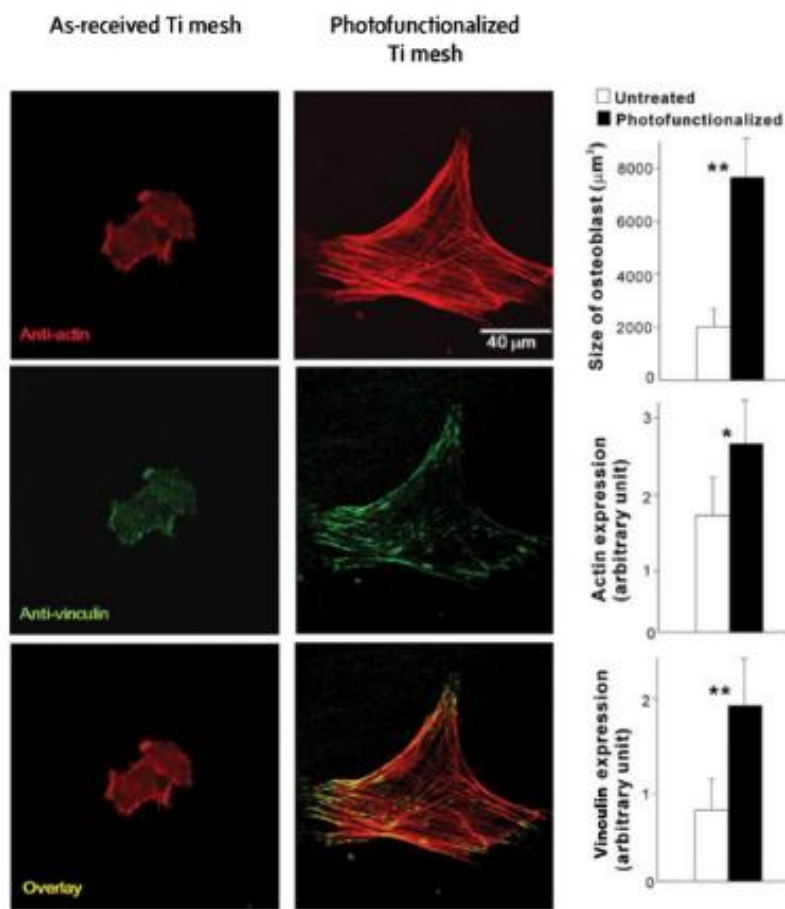


Figure 5a: Attachment and spreading behavior of human osteoblasts enhanced on photofunctionalized Ti mesh. High magnification confocal microscopic images are shown with immunochemical stain for cytoskeletal actin (red) and adhesion protein, vinculin (green).

Figure 5b: The results from cytomorphometry and protein expression densitometry based upon the analyses using the microscopic images. *p < 0.05; **p < 0.01, statistically significant between as-received and photofunctionalized Ti mesh.

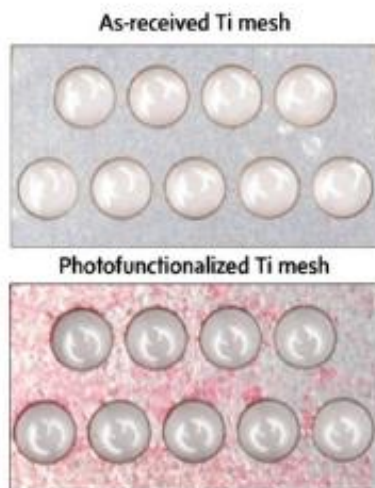


Figure 6a: Culture images after ALP stain and the result from ALP chemical quantification.

□ Untreated
■ Photofunctionalized

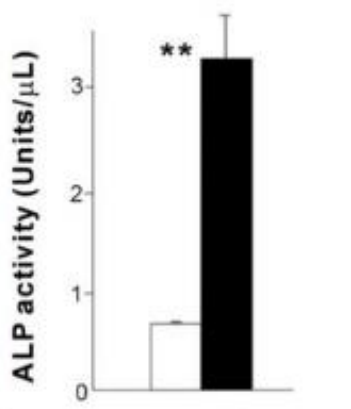


Figure 6b: ALP activity in human osteoblasts compared between as-received and photofunctionalized Ti mesh. ** $p < 0.01$, statistically significant between as-received and photofunctionalized Ti mesh.




Figure 7a: UV light.



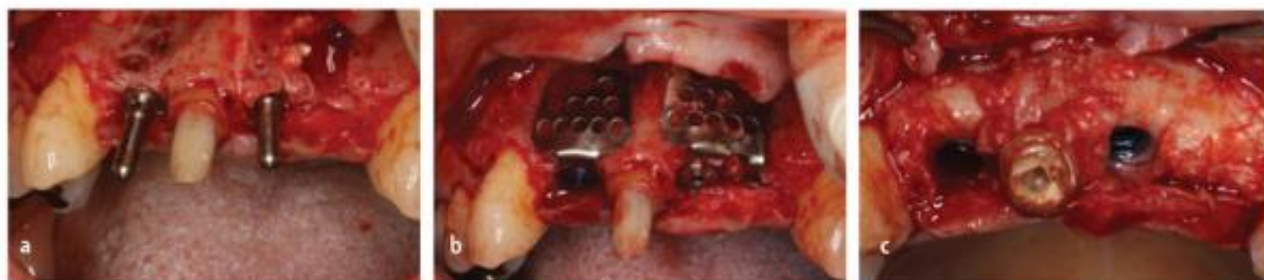Figure 7b: A photo device used for photofunctionalization. The device provides an automatic 15- to 20-minute program of conditioning with optimized wavelength and strength of UV light treatment.




Figure 8: Hydrophobic-to-hydrophilic conversion of Ti mesh after photofunctionalization.

using Ti mesh, which was also photofunctionalized and confirmed to be highly hydrophilic (**Fig 8**). After the Ti mesh was fixed with a cover screw, the defect was filled with xenograft bone substitute material (Bio-Oss Cancellous 0.25–1.0 mm particles, Geistlich; Princeton, NJ) and covered with resorbable collagen membrane (Ossix, OraPharma, Warminster, PA). After four months of healing, mature bone formation of sufficient width and height was confirmed clinically and a connective tissue graft procedure performed. Pre- and postoperative clinical images are presented in **Figures 9a–9c**.

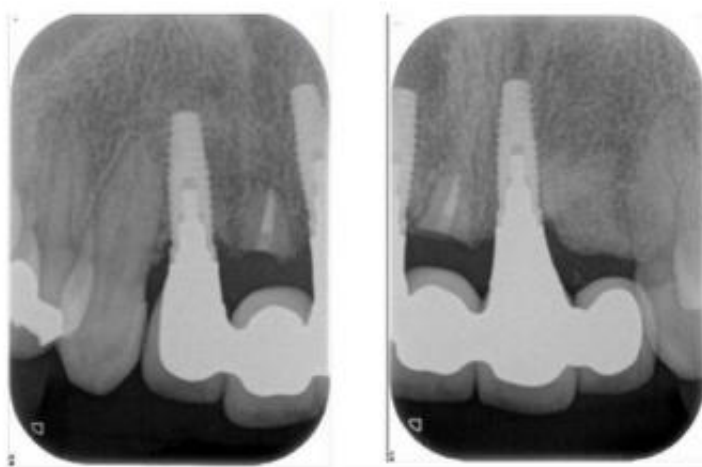
The soft tissue healed for two months before the provisional restoration was placed (**Fig 10a**).¹⁹ Tooth #8 was saved as a submerged root to maintain the surrounding alveolar bone. The final fixed restoration was placed, and the esthetics and function have been maintained satisfactorily after a one-year follow-up (**Figs 10b & 10c**).



Figures 9a-9c: Case 1, clinical images during (a) implant placement and (b) simultaneous GBR using Ti mesh. The implants and Ti mesh were photofunctionalized. Note the matte Ti mesh surface due to widespread blood, as opposed to a glossy surface typically seen on as-received Ti mesh (b). Mature bone formation of sufficient width and height along with osseointegration were clinically confirmed after four months (c).

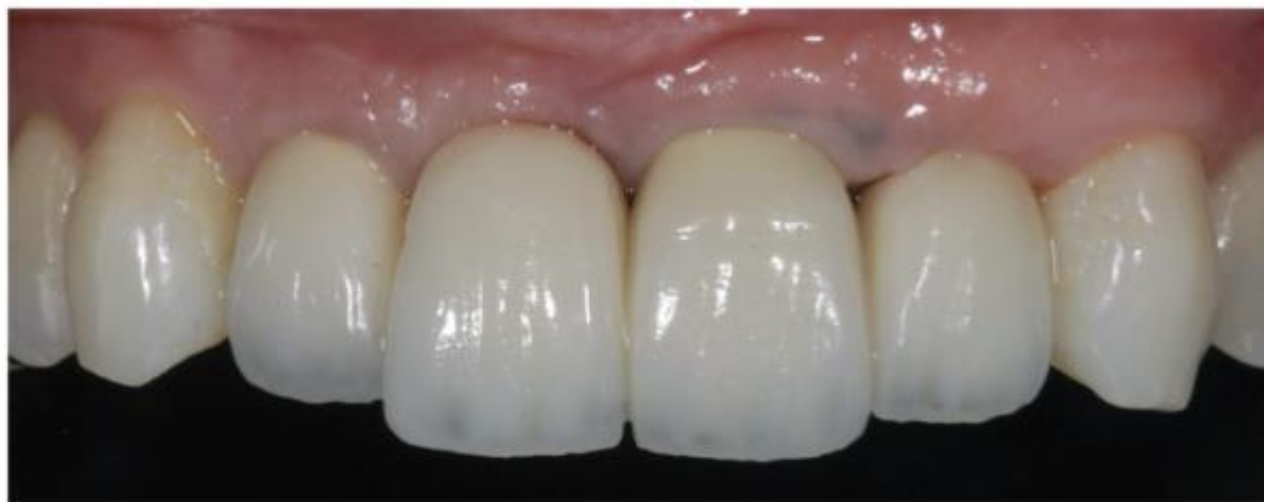

Figure 10a: Final restoration in place.



Figures 10b & 10c: A radiographic image of the final restoration along with the peri-implant x-ray image in Case 1.

“ The use of photofunctionalized implants and Ti mesh enabled more strategic and aggressive treatment planning and resulted in successful treatment outcomes with secure application of immediate and early loading protocols. ”

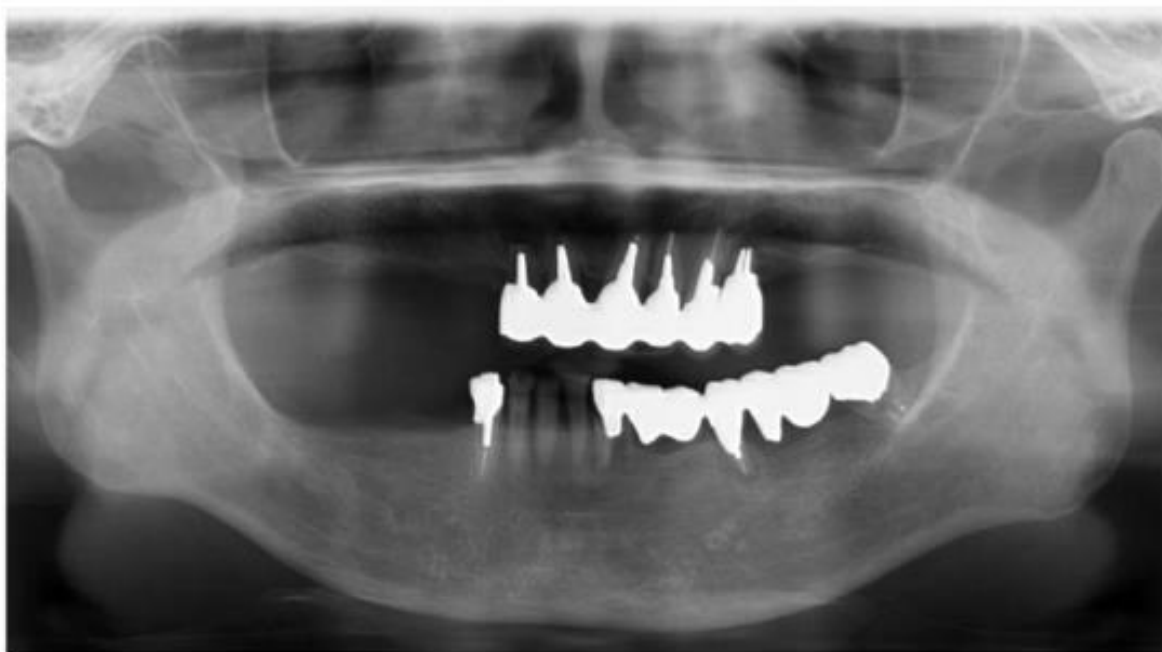
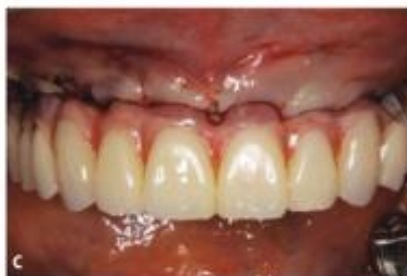
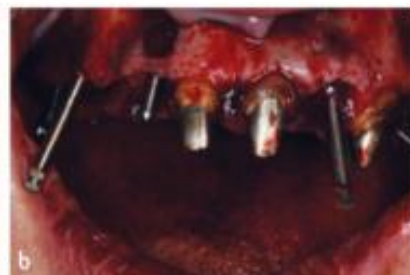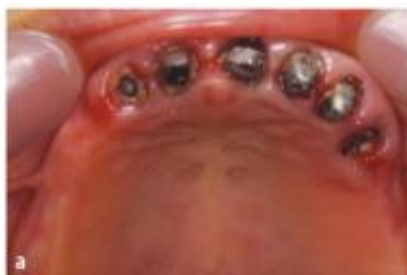Figure 11: Case 2, panoramic x-ray image.

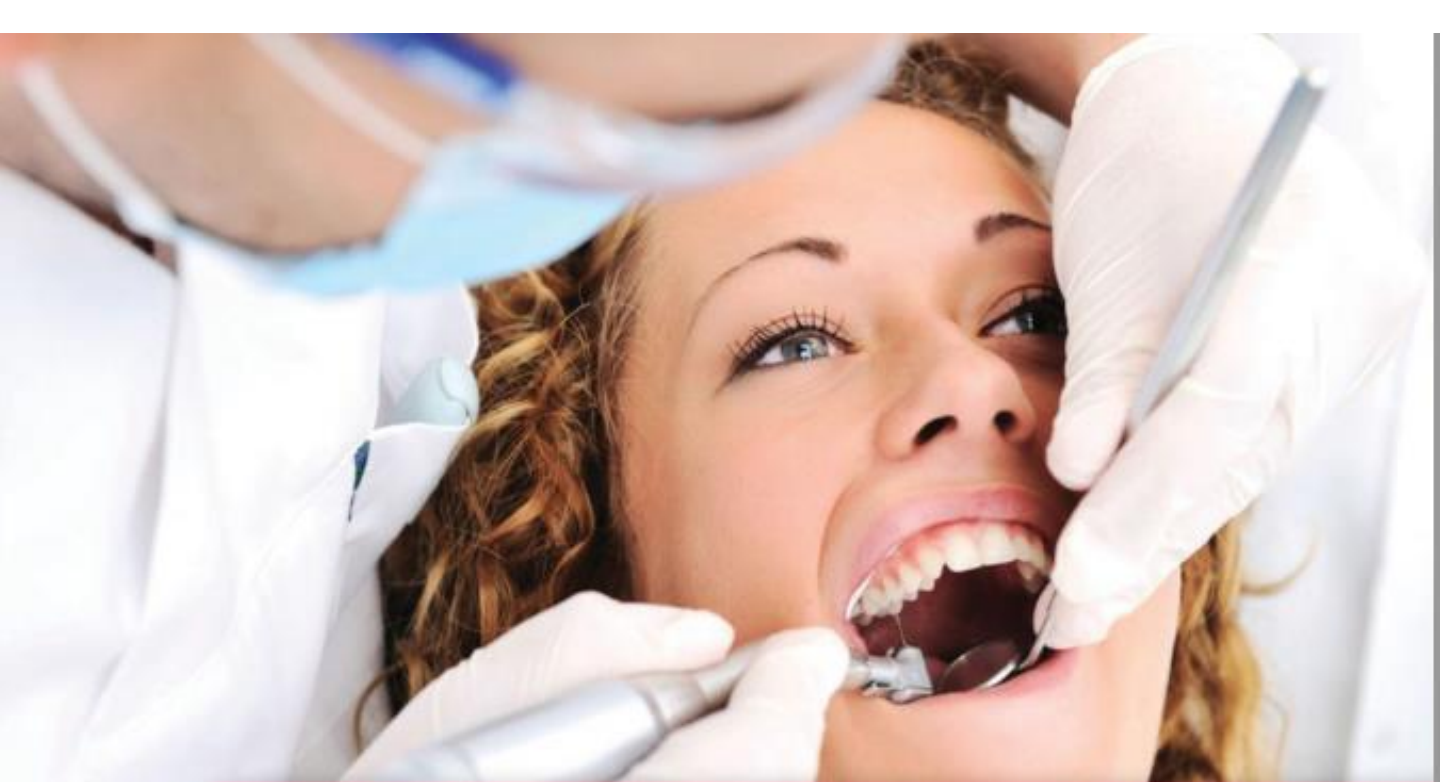Case 2: Effective Application of Immediate and Early Loading Protocols on Photofunctionalized Implants

A 64-year-old female wearing upper and lower removable dentures presented for possible replacement with implant restorations (Fig 11). A bone-anchored bridge with pink porcelain was planned for both the maxilla and mandible, and the application of early and immediate loading protocols was planned for the maxilla and mandible, respectively. A two-stage extraction was planned for the six maxillary hopeless teeth; three teeth were extracted on the day of implant placement, while the other three were extracted when the provisional restoration was placed onto the implants (Fig 12a).

After the three maxillary teeth were extracted, six photofunctionalized implants (4 mm in diameter and 13 mm in length, Osseotite Certain) were placed; two implants were placed in fresh extraction sockets at the bilateral



Figures 12a-12c: Intraoral images of the maxilla before (a) and during (b) implant surgery. Six photofunctionalized implants were placed in either fresh extraction sockets, native bone, or sinus elevation sites. Two months after implant placement, a provisional restoration was put in place on the implants (c).



Materials Matter, Competency Counts



As a cosmetic dentist your goal is to achieve maximum aesthetics for the patient. Materials are important, but equally essential is working with a competent dental technician that can consistently produce a quality restoration for your patient.

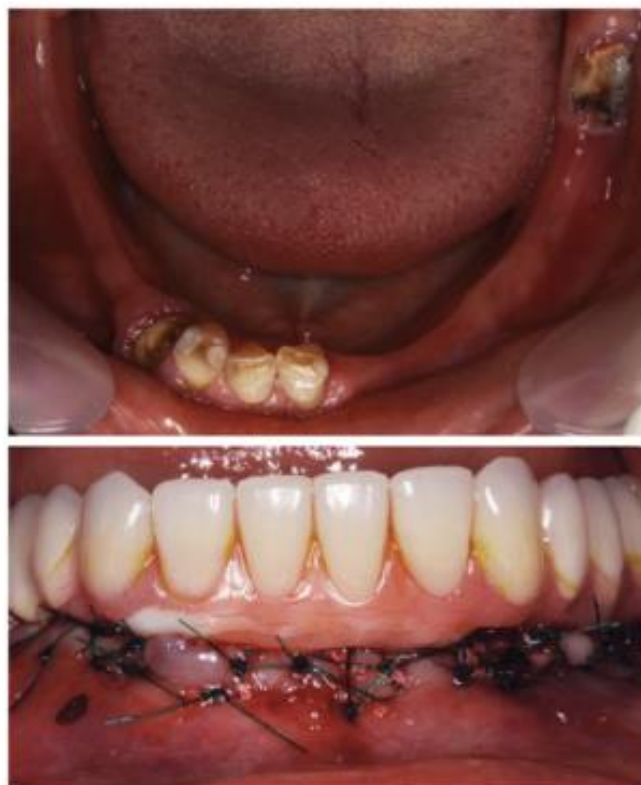

Only four states in the country require dental technicians to be certified or take any continuing education. Ensure that your patients get the best restoration available. Ask your dental laboratory if they are a Certified Dental Laboratory or if they employ Certified Dental Technicians.

www.whatsinyourmouth.us

Brought to you by the National Association of Dental Laboratories.

lateral incisor areas, while two implants were placed in the bilateral premolar areas with native bone support (Fig 12b). Another two implants were placed in the posterior maxilla with simultaneous sinus elevation, using the lateral window technique. A temporary prosthesis was placed using the three natural teeth as anchors while the implants were kept unloaded. After two months, the implants were uncovered and the provisional restoration was screwed onto the six implants at the time of extraction of the remaining three teeth (Fig 12c). Two months later, all remaining teeth in the mandible were extracted and four photofunctionalized implants were placed (all were 4 mm in diameter and 13 mm in length, except for the one at the lower right anterior position, which was 5 mm in diameter and 13 mm in length) (Fig 13a). The implants were immediately loaded with a full-arch acrylic temporary prosthesis (Fig 13b). After confirming successful osseointegration and soft tissue healing (Fig 14), a computer-aided design/computer-aided manufacturing (CAD/CAM)-assisted final restoration was fabricated and placed (Fig 15).



Figures 13a & 13b: Mandibular images before (a) and after (b) implant placement. Four photofunctionalized implants were placed and immediately loaded with full-arch acrylic provisional (b).

Seven Tips for Photofunctionalization

The results of the previous studies and the outcomes of the two cases discussed here show that photofunctionalization is a novel and effective tool that has the potential to improve multiple aspects of current implant therapy. The ability to overcome biological aging, a simple chairside procedure, and its versatile application are additional benefits of the technology. Its use need not be limited to expediting and enhancing osseointegration, but can also be extended to enhancing bone formation around Ti mesh. Here are seven practical tips for the effective use of photofunctionalization:

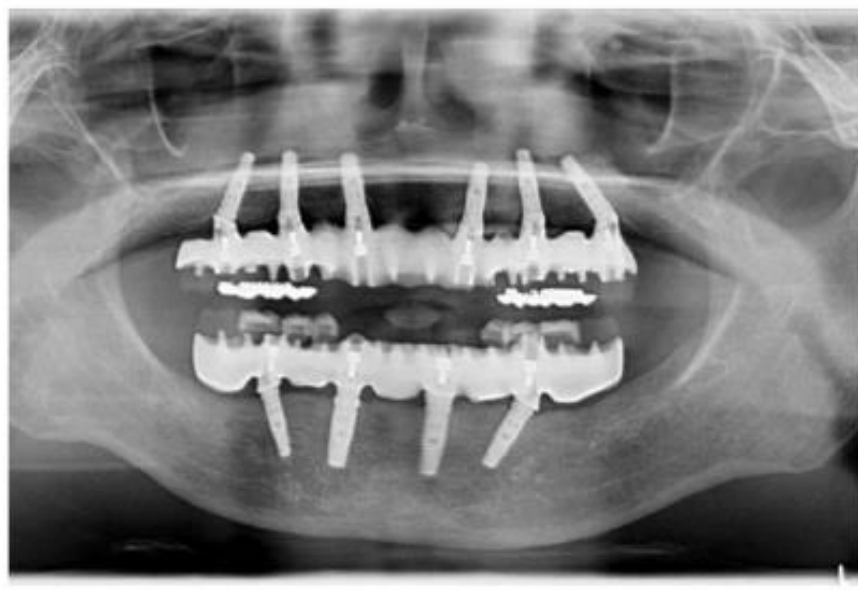

Figure 14: Panoramic x-ray image confirming successful osseointegration.

1. Photofunctionalization requires adequate conditioning (15 to 20 minutes for TheraBeam Affiny). Therefore, implants of appropriate diameter and length need to be selected prior to commencing surgery.
2. The use of one-step shorter implants (e.g., 10 mm instead of 11.5 mm) may be considered to make surgery less invasive due to improved osseointegration of the photofunctionalized implants.
3. When there is uncertainty about the size and length of implants to be used in the surgery, multiple potential implants should be photofunctionalized in preparation for the final decision.
4. The same number of implant drivers as implants need to be ready, to allow the implants to stand in the photo device (Fig 16).
5. After photofunctionalization is complete, the implant and implant driver need to be handled and set in the hand-piece with caution, and care should be taken not to drop the implant or make contact with unsterilized instruments or materials.
6. After photofunctionalization, the implants should be placed immediately (and certainly within 30 minutes) for maximal surface bioactivity. If the implants were stored without opening the photo device, the bioactivity appears to be maintained up to two hours. Therefore, if multiple implants are to be placed, the timing and sequence of implant placement and concomitant surgery need to be planned in advance. For example, if implants are to be placed in the maxilla and mandible with simultaneous GBR, photofunctionalization should be performed separately for the maxillary and mandibular implants.
7. Pay particular attention to the details of the fundamentals and principles of implant surgery. In particular, make sure that the implant site is filled with blood so that the photofunctionalized implant absorbs blood effectively and efficiently. Be sure to avoid contact of implants with saliva or contaminated tissues and fluids, which might dilute blood or cause biological and chemical contamination.

Summary

Ultraviolet light treatment of dental implants immediately prior to placement, or photofunctionalization, is a novel clinical tool with the potential to improve implant therapy. Photofunctionalization improves the surface properties of implant surfaces by removing hydrocarbons, regenerating hydrophilicity, and optimizing electrostatic properties. We first tested the effect of photofunctionalization to potentially enhance the

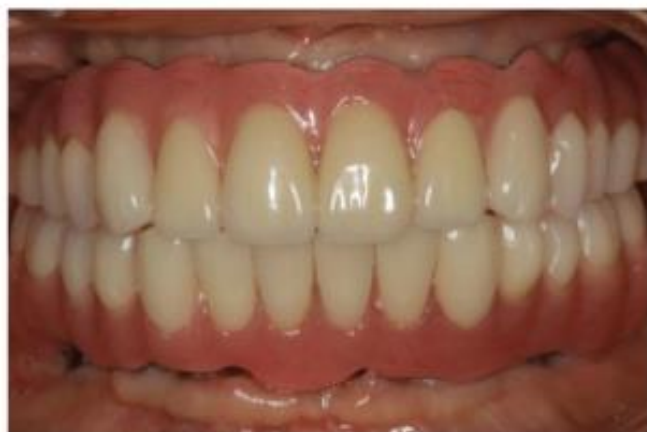

Figure 15: Presentation of the final prosthesis.




Figure 16: Dental implants with an implant driver set on a removable metallic stand. The stand will be placed in the photo device for photofunctionalization.

osteoconductivity of Ti mesh in an in vitro culture study using human osteoblasts. The results showed that the attachment, spreading behavior, adhesion, and function of osteoblasts were remarkably increased on photofunctionalized Ti mesh compared to untreated ones, suggesting the considerable enhancement of osteoconductivity by photofunctionalization. We then applied photofunctionalization to dental implants and Ti mesh in two complex clinical cases requiring simultaneous GBR, sinus elevation, immediate implant placement into the extraction socket, and esthetic consideration. The use of photofunctionalized implants and Ti mesh enabled more strategic and aggressive treatment planning and resulted in successful treatment outcomes with secure application of immediate and early loading protocols. The cases discussed here, in combination with the results from human cell study, help to show that photofunctionalization is a useful and effective tool for improving implant therapy and that, with the advent of this technology, novel avenues of treatment can be pursued and some clinical challenges overcome. Long-term controlled trials and/or histologic studies are warranted to verify that photofunctionalization is a clinically significant and beneficial therapy.

References

- Funato A, Yamada M, Ogawa T. Success rate, healing time, and implant stability of photofunctionalized dental implants. *Int J Oral Maxillofacial Implants*. 2013 Sep-Oct;28(5):1261-71.
- Funato A, Ogawa T. Photofunctionalized dental implants: a case series in compromised bone. *Int J Oral and Maxillofacial Implants*. 2013 Nov-Dec;28(6):1589-601.
- Suzuki S, Kobayashi H, Ogawa T. Implant stability change and osseointegration speed of immediately loaded photofunctionalized implants. *Implant Dent*. 2013 Oct;22(5):481-90.
- Att W, Ogawa T. Biological aging of implant surfaces and their restoration with ultraviolet light treatment: a novel understanding of osseointegration. *Int J Oral Maxillofacial Implants*. 2012 Jul-Aug;27(4):753-61.
- Lee JH, Ogawa T. The biological aging of titanium implants. *Implant Dent*. 2012 Oct;21(5):415-21.
- Att W, Hori N, Takeuchi M, Ouyang J, Yang Y, Anpo M, Ogawa T. Time-dependent degradation of titanium osteoconductivity: an implication of biological aging of implant materials. *Biomaterials*. 2009 Oct;30(29):5352-63.
- Hori N, Att W, Ueno T, Sato N, Yamada M, Satuwatari I, Suzuki T, Ogawa T. Age-dependent degradation of the protein adsorption capacity of titanium. *J Dent Res*. 2009 Jul;88(7):663-7.
- Aita H, Hori N, Takeuchi M, Suzuki T, Yamada M, Anpo M, Ogawa T. The effect of ultraviolet functionalization of titanium on integration with bone. *Biomaterials*. 2009 Feb;30(6):1015-25.
- Iwasa E, Hori N, Ueno T, Minamikawa H, Yamada M, Ogawa T. Enhancement of osteoblast adhesion to UV-photofunctionalized titanium via an electrostatic mechanism. *Biomaterials*. 2010 Apr;31(10):2717-27.
- Hori N, Ueno T, Suzuki T, Yamada M, Att W, Okada S, Ohno A, Aita H, Kimoto K, Ogawa T. Ultraviolet light treatment for the restoration of age-related degradation of titanium bioactivity. *Int J Oral Maxillofacial Implants*. 2010 Jan;25(1):49-62.
- Pyo SW, Park YB, Moon HS, Lee JH, Ogawa T. Photofunctionalization enhances bone-implant contact, dynamics of interfacial osteogenesis, marginal bone seal, and removable torque value of implants: a dog jawbone study. *Implant Dent*. 2013 Dec;22(6):666-75.
- Ohyama T, Uchida T, Shibuya N, Nakabayashi S, Ishigami T, Ogawa T. High bone-implant contact achieved by photofunctionalization to reduce periimplant stress: a three-dimensional finite element analysis. *Implant Dent*. 2013 Feb;22(1):102-8.
- Suzuki T, Hori N, Att W, Kubo K, Iwasa E, Ueno T, Maeda H, Ogawa T. Ultraviolet treatment overcomes time-related degrading bioactivity of titanium. *Tissue Eng Part A*. 2009 Dec;15(12):3679-88.
- Ikeda T, Hagiwara Y, Hirota M, Tabuchi M, Yamada M, Sugita Y, Igawa T. Effect of photofunctionalization on fluoride-treated nanofeatured titanium. *J Biomater Appl*. 2013 Aug 28. [Epub ahead of print].
- Aita H, Att W, Ueno T, Yamada M, Hori N, Iwasa E, Tsukimura N, Ogawa T. Ultraviolet light-mediated photofunctionalization of titanium to promote human mesenchymal stem cell migration, attachment, proliferation and differentiation. *Acta Biomater*. 2009 Oct;5(8):3247-57.
- Ishikawa T, Salama M, Funato A, Kitajima H, Moroi H, Salama H, Garber D. Three-dimensional bone and soft tissue requirements for optimizing esthetic results in compromised cases with multiple implants. *Int J Periodontics Restorative Dent*. 2010 Oct;30(5):503-11.
- Funato A, Salama MA, Ishikawa T, Garber DA, Salama H. Timing, positioning, and sequential staging in esthetic implant therapy: a four-dimensional perspective. *Int J Periodontics Restorative Dent*. 2007 Aug;27(4):313-23.
- Funato A, Ishikawa T. 4D implant therapy: esthetic considerations for soft-tissue management. Tokyo: Quintessence Pub.; 2011.
- Salama M, Ishikawa T, Salama H, Funato A, Garber D. Advantages of the root submergence technique for pontic site development in esthetic implant therapy. *Int J Periodontics Restorative Dent*. 2007 Dec;27(6):521-7. **JCD**



Dr. Funato maintains a private practice in Kanazawa, Ishikawa, Japan.



Dr. Tonotsuka maintains a private practice in Tokyo, Japan.



Dr. Murabe maintains a private practice in Hitachinaka, Japan.



Dr. Hirota is an associate professor, Department of Oral and Maxillofacial Surgery, Yokohama City University School of Medicine, Yokohama, Japan, where he also practices.



Dr. Ogawa is a professor at The Weintraub Center for Reconstructive Biotechnology, Division of Advanced Prosthodontics, UCLA School of Dentistry, Los Angeles, California, where he also practices.

Disclosures: The authors did not report any disclosures.